07/19/23 STATEMENT Page: 1
Oper: SGR

OPEN ADVANCED MRI OF VANCOUVER
221G NE 104TH AVE #106
VANCOUVER, WA 98664-4587
Tel: (360) 253-2525

IRS# 462791692

PULLIAM,VIKTORIYA
15204 SE MICHELLE DR
CLACKAMAS,OR 97015

Acct: 20025221-1/CM
Pat: PULLIAM,VIKTORIYA 12/06/89
Tel: (503) 208-1326

Ins2: AETNA W245811436

| Date | Code | Description | Qt | Diag | Prv Ref AR Plc | Amt | Bal |
|---|---|---|---|---|---|---|---|
| 01/22/20 | 72156 | MR CERVICAL W WO CONTR | 1 | S13.160AAEL99997CMO S13.0XXA M48.32 M50.122 | | 1800.00 | |
| 02/17/20 | | | | | | | |
| 01/22/20 | A9578 | | 5 | S13.160AAEL99997CMO S13.0XXA M48.32 M50.122 | | 50.00 | |
| 02/17/20 | | | | | | | |
| 01/22/20 | 76377 | 3D MULTIPLANAR RECONS | 1 | S13.160AAEL99997CMO S13.0XXA M48.32 M50.122 | | 227.35 | |
| 02/17/20 | INCK | | | | | | |
| 07/19/23 | S9981 | MEDICAL RECORDS COPY F | 1 | | OAM 99997CMO | | |
| 07/19/23 | LEGL | | | | | | |

Regular Balance $

Providers: AEL - LARHS, ANTHONY E, MD
OAM - OPEN ADVANCED MRI OF VANCOUVER

Referral Physicians: 99997 - GENTRY, SOLON DC

Open Advanced MRI NW

A Division of Precision Imaging & Interventional Pain, Inc.

## MRI- SPINE- CERVICAL

**Patient Name:** VIKTORIYA PULLIAM
**Date of Birth:** 12/06/1989
**Referring Physician:** SOLON GENTRY DC
**Date of Service:** 01/22/2020
C/B: c1, 3

**CLINICAL INDICATION:** At intake patient reports and/or draws on the body diagram neck pain with radicular-type symptoms. Specifically patient indicates pain radiation into the right shoulder and right upper extremity numbness. Symptoms described as a subsequent to involvement in MVA on 11.21.2019. Patient is claustrophobic, reason for open MRI system request. Referred by the division of chiropractic medicine.

**TECHNIQUE:** MR imaging of the cervical spine is obtained on the open magnet system. This to include sagittal T1 FSE, sagittal T2 FSE, axial T2 FSE and coronal T1 FSE. 5 cc Multihance is injected intravenously via peripheral access through the right antecubital fossa, this without on site observed complications. Postcontrast T1 FSE fat sep imaging is subsequently obtained. Patient's BMI is 21 based on the NIH calculator. In addition thin section, high spatial resolution, enhance fluid signal, gradient echo-type imaging of the central canal, reconstructed as MIP/myelographic sequence, standard orthogonal and curved MPR projections, the latter 3-D reconstructions on separate/dedicated workstation performed by the radiologist. Comparison: None similar.

**FINDINGS:** Reduced cervical lordosis and slight leftward neck-head tilt, nonspecific.
Superimposed slight/1-2 mm displacement in the direction of retrolisthesis at C5-6, key image 1.
No Modic type I reaction or subchondral marrow edema within the articular facets.
Suggested slight diastases of the left C5-6 facet joint, key image 2.
Short pedicle, congenitally narrow bony spinal canal configuration.

The general cord caliber is in the normal range.
Discogenic mass-effect on cord is detailed in the level by level analysis below.
This noted there is increased T2 signal within the ventral left parasagittal cord;
- this 1.5-2 mm in extent, key images 3-4.
Right cerebellar ectopia without mass-effect on the adjacent brainstem, key image 5.
There is no syrinx.

Posterior epidural fat at C7-T1 is size permissible for image guided procedures.
The vertebral arteries enter the foramina transversarium at C6; the right is dominant.
No incidental/ominous soft tissue abnormality on this limited assessment of the neck.

C1-2: Unremarkable.
C2-3: No annular injury or disc herniation. No facet joint effusion or strain pattern.
C3-4: No annular injury or disc herniation. No facet joint effusion or strain pattern.
C4-5: No annular injury or disc herniation. No facet joint effusion or strain pattern.

C5-6: Increased T2 signal within the posterior paracentral annulus, key image 6.
Superimposed posterior paracentral disc herniation, 9-10 mm/base and 3 mm/radial extent, key images 6-7.
Disc flattens the ventral cord surface and encroaches the ventral C6 nerve rootlets right more than left.
Rim peri-annular hyperemia along the herniated disc, key image 7.
Mildly thickened ligamentum flavum that effaces the dorsal CSF space.
The mid sagittal central canal measures 5 mm, substantially narrowed.
No significant neural foramina narrowing.
No facet joint effusions or intra-articular/capsular hyperemia.

C6-7: No annular injury or disc herniation. No facet joint effusions. Borderline right facet joint hyperemia.
C7-T1: No annular injury or disc herniation. No facet joint effusion or strain pattern.

**IMPRESSION:**

1. Subluxation of C5-6 cervical vertebra, initial encounter (S13.160A)

Singular level alignment deformity indicative of disc/posterior longitudinal ligament injury.

2. Traumatic rupture of cervical intervertebral disc, initial encounter (S13.0XXA)
Traumatic spondylopathy, cervical region (M48.32)
Cervical disc disease C5-6 (M50.122)

Annular injury/tear and superimposed disc herniation at C5-6.
This results in mass-effect on the ventral cord also on the ventral C6 nerve rootlets right side worse.
Associated active peri-annular granulation compatible with a subacute temporality.
In the context of recent MVA, this more probable than not posttraumatic in etiology.

3. Suggested subluxation of the left C5-6 facet joint.
Ongoing inflammation indicative of active strain/likely compensatory of the right C6-7 facet joint.

**Recommendation:** Patient may return to our clinic for consultation/consideration of image guided pain therapy.
This performed at the discretion of the referring clinician in addition to ongoing conservative therapy.
This considered as most appropriate when conservative therapy is not conclusive and surgery not yet contemplated.
If recommended by the provider, therapy to be initiated as C7-T1 interlaminar ESI.
Suboptimal response to conservative + minimally invasive therapy may further substantiate the medical necessity for surgery.

**Note to Provider**: The medical imaging information, to a large extent, may be better communicated when the key images, as reported above, are reviewed by the provider, other consultants and/or patients. Please let me know, at the email address below my signature, if you need to review the key images, the PACS system(s) you have access to and if further clarification required for the imaging report.

Thank you for engaging us to contribute to the care of your patient. Always let us know if we could have done better.

VR-Dragon Medical dictation integrated with the EMR-PACS system. If/when typographical errors are suspected whereby these may inadvertently affect at the intended clinical information of this report, please immediately contact the radiologist for prompt clarification and correction.
Electronically Signed - 01/22/20 9:39

**Anthony E. Larhs, MD**
**alarhs@oamrinw.com**
**Cell: 206-877-3469**
**If we are unable to take your call or text,**
**we will respond to your message promptly.**

MRN 25221/1 Patient: PULLIAM,VIKTORIYA DOS 01/22/2020

## Shade in affected areas of symptoms

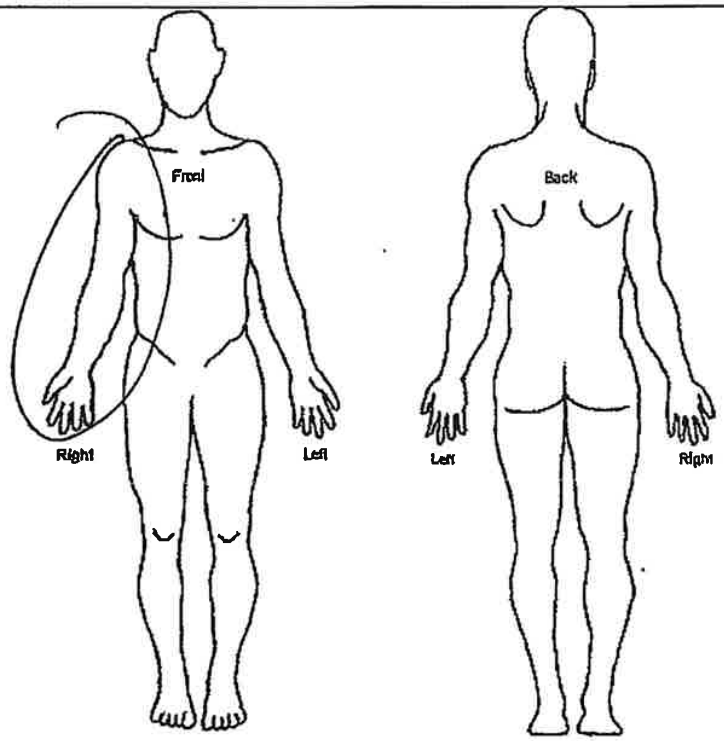


**MRI CONTRAST CONSENT FORM (When Applicable)**

Your doctor has requested an MRI scan that requires the use of an intravenous (IV) contrast agent or "dye." This agent is a substance called gadolinium and is usually given through a needle placed in a vein, artery, or joint space. Contrast material is generally considered to be quite safe; however, there are risks of which you should be aware. Any injection carries with it the risk of damage to a vein, artery, nerve, or skin, risk of infection, and risk of allergic reaction. Many patients receiving IV gadolinium may experience a momentary cold feeling in the area of the injection. The injection may also cause nausea or headache for some patients.

Please answer the following questions:

| | | | |
|---|---|---|---|
| Have you had a prior reaction to gadolinium (MRI contrast)? | Y / N | Do you have any kidney problems, especially kidney failure? | Y / N |
| Is there a possibility you are pregnant? | Y / N | Are you breast-feeding? | Y / N |

last Period Jan 11th

On very few occasions, a patient may experience an allergic reaction to gadolinium. The most common of these reactions are sneezing, nasal congestion, hives, and temporary breathing difficulty. The most severe cases of allergic reaction (anaphylaxis) are extremely rare but may be life threatening. Our medical staff at ***Open Advanced MRI*** is trained to treat such allergic reactions to contrast.

Emergency Contact Information:

Name Viktoriya Pulliam Phone # [illegible]

Your signature below indicates that you have read and understand the above information, have had any questions answered, and consent to the procedure.

Signed_____ Date 01/22/2020

*Office Use Only: Please do not write in the box below*

IV 22 G Location [illegible] Contrast Multihance Amount 5cc Tech Dr Larms

Radiologist / NP Signature Date 01.22.2020

Patient Demographics

| Patient Name | Date Of Birth | Sex | Marital Status |
|---|---|---|---|
| Pulliam, Viktorya | 12/08/1989 | Female | Married |
| Address | City | State | Zip Code |
| 15204 SE Michelle Dr. | Clackamas | OR | 97015 |
| Home Phone | Work Phone | Cell Phone | E-Mail Address |
| | | 503-208-1326 | admin@qualitymassandcan.com |
| Language | Race | Ethnicity | Employer |
| Emergency Contact | Emergency Contact Phone | | |

| Name | | | |
|---|---|---|---|
| Pulliam, Viktorya | | | |
| Address | City | State | Zip Code |
| 15204 SE Michelle Dr. | Clackamas | OR | 97015 |
| Home Phone | Work Phone | Cell Phone | E-Mail Address |
| | | 503-208-1326 | admin@qualitymassandcan.com |

| Policy Holder/Primary Insured | Patient Relationship To Insured | Date Of Birth | |
|---|---|---|---|
| Pulliam, Viktorya | Self | 12/08/1989 | |
| Insurance Carrier | Subscriber # | Group # | Plan Name |
| | | | |
| Deductible | Copay | Employer | |

date of injury: 11/21/19.

SECONDARY INSURANCE

| Policy Holder/Secondary Insured | Patient Relationship To Insured | Date Of Birth | |
|---|---|---|---|
| | | | |
| Insurance Carrier | Subscriber # | Group # | Plan Name |
| | | | |
| Deductible | Copay | Employer | |

Please call patient to schedule Cx spine MRI due to sporadic upper extremity radicular symptoms. Patient is represented by attorney Brandon Squires.

Please call w/ any questions.

Dr Gentry (New Spine Chiro)

New Spine Chiropractic
12766 SE Stark St., Plaza 125 (C)
Portland, OR 97233
P: 503 232 2933 F: 971 271 7054

Viktoriya Pulliam
Patient ID: 95887598 DOB: 12/06/1989 Sex: F Account No.:
Encounter ID: 214637814 Encounter Date: 01/08/2020
Encounter Type: Office Visit

**SUBJECTIVE:**

**Chief Complaint:** Vicky states that she is feeling tight and sore in mid back between shoulder blades, mild HA and tightness in neck, left and right arms are feeling achey but not as much burning in right arm. Due to ongoing Sx in upper extremities, MRI of Cx spine is recommended.

**OBJECTIVE:**

**Objective Notes:** Static palpation reveals: +2/4 Tight and Tender suboccipitals Sternocleidomastoids, levator scapula, upper traps. Rhomboids, scalenes, cervical thoracic lumbar paraspinals, quarutus lumborum, and elft wrist extensors. Segmental Analysis reveals: restrictions at C2-3R/LRR, T4-6 ext wirh R ribs, L5-S1R/LRR, R SI ext, L wrist scpahoid P to A glide.

**ASSESSMENT:**

**Diagnosis:** ICD-10 Codes:
1)S060X0D; Concussion without loss of consciousness, subsequent encounter
2)S138XXA; Sprain of joints and ligaments of other parts of neck, initial encounter
3)S233XXA; Sprain of ligaments of thoracic spine, initial encounter
4)S335XXA; Sprain of ligaments of lumbar spine, initial encounter
5)R51; Headache
6)M609; Myositis, unspecified
7)M62838; Other muscle spasm
8)M9907; Segmental and somatic dysfunction of upper extremity
9)M9901; Segmental and somatic dysfunction of cervical region
10)M9902; Segmental and somatic dysfunction of thoracic region
11)M9903; Segmental and somatic dysfunction of lumbar region
12)M9904; Segmental and somatic dysfunction of sacral region

**Assessments:** ICD-10 Assessments:
Patients prognosis: await response to care. . Patient is also having numbness and tingling in right arm into her 4th and 5th digits (possible MRI will be needed.)

**PLAN:**

**Procedures:**
1) 98941; Sp. Manipulation 3 - 4
2) 98943; Extra Sp. Manipulation
3) 97124; Massage

**Procedure Notes:** Light CMT to CTLS spine and L wrist, see detailed listing above, Massage therapy provided by LMT see notes below:

Pt is feeling pain in shoulders and between shoulder blades, and TT in CTLS spine. HT found in BL rhombs, suboccs, CTL PS, traps, R upper traps, scalenes, BL UTs/levs, R delts, lower lats, CTL pS and QLs. med tissue applied to muscles listed above. 4 units 50 lpm-557pm, Gabrielle Brownwing LMT 23896

**Care Plan:** Treatment is directed to return the patient to pre-injury status. Post Treatment Symptoms/Signs: Pt. reports a decrease in stiffness and soreness.

**Patient Instructions:** Patient responded well to treatment today without complication. MRI referral will be made due to ongoing cervical radicular symptoms.

[Electronically Signed] - Date: 1/8/2020 6:13:50 PM

[Provider]: Solon Gentry

PATIENT INTAKE

NAME Viktoriya Pulliam DATE 1-22-2020

MAILING ADDRESS 15204 SE Michelle Dr. Clackamas, OR 7015

EMAIL ADDRESS

CELL PHONE HOME PHONE

HEIGHT 5'5 WEIGHT 145 DOB 12-16-89

PRESENTING COMPLAINT, DURATION? 8 weeks on/off Rt arm numbness

RELATED TO AN ACCIDENT OR INJURY? WHEN? Yes Nov. 21

ANY PRIOR SURGERIES TO THIS AREA OF YOUR BODY? NO

PRIOR IMAGING RELATED TO THIS CONDITION? WHEN/WHERE? NO

DO YOU HAVE A HISTORY OF CANCER? WHAT TYPE / WHEN DIAGNOSED AND LAST TREATED? NO

DO YOU HAVE A HISTORY OF KIDNEY DISEASE? NO

DO YOU HAVE DIABETES? NO

ARE YOU PREGNANT OR NURSING? NO, NO

ARE YOU CLAUSTROPHOBIC? YES

WILL YOU REQUIRE SEDATION? NO

DO YOU USE A WHEELCHAIR OR WALKER? NO

ARE YOU ABLE TO TRANSPORT YOURSELF TO AND FROM THE MRI/CT BED? YES

DO YOU HAVE A HISTORY OF ALLERGIC REACTION TO MRI OR CT CONTRAST? YES

ANY POSSIBILITY YOU HAVE METAL IN YOUR EYES? NO

DO YOU HAVE A PACEMAKER, DEFIBRILLATOR, OR TENS DEVICE ? WHEN PLACED? NO

LAST TIME YOU HAD BLOOD WORK / WHERE? 4/1/2019, Providence

LIST YOUR MAIN MEDICATIONS None.

REFERRING PROVIDER Dr. Chase SPECIALTY Chiro FOLLOW-UP APPT 10am 1-22-2020

Genty

SIGNATURE OF PATIENT / LEGAL GUARDIAN (ON SITE ONLY)

VP